

Original Research

The Use of Dehydrated Human Amnion/Chorion Membrane Allograft Injection for the Treatment of Tendinopathy or Arthritis: A Case Series Involving 40 Patients

Alfred C. Gellhorn, MD, Alex Han, BA

Abstract

Background: Degenerative joint and tendon injuries remain difficult to treat, with few effective conservative treatment options available. Regenerative approaches aim to promote the inherent healing capacity of injured tissues. Micronized dehydrated human amnion/chorion membrane (dHACM) injection is an emerging regenerative option with promising preclinical results.

Objective: To test the clinical effectiveness of dHACM injection in patients with chronic tendinopathy and arthropathy.

Design: Case series.

Setting: Academic medical center outpatient sports medicine clinic.

Patients: A total of 40 patients with chronic tendinosis or arthropathy who received dHACM over a period of 9 months.

Methods: A structured interview was administered to patients by telephone to supplement the clinical information available in the medical chart. All patients received an ultrasound-guided injection of dHACM.

Main Outcome Measures: The primary outcome was change in pain level, and the secondary outcome was change in activities of daily living (ADLs) and sports/recreation function. More than 30% improvement in average pain and function was considered a successful outcome.

Results: Patient pain and function were measured at 1, 2, and 3 months after the procedure. Patient-reported average pain scores decreased from a baseline value of 6.4 (95% confidence interval [CI] = 5.7-7.0) to 2.7 (95% CI = 2.1-3.3; $P < .001$) at 1 month, 1.7 (95% CI = 1.1-2.2; $P < .001$) at 2 months, and 1.4 (95% CI = 0.9-1.9; $P < .001$) at 3 months. The percentage of patients achieving clinical success, defined as 30% or greater improvement in pain levels, was 68% at 1 month, 82% at 2 months, and 91% at 3 months. Patient-reported functional impairment in ADLs decreased from 6.8 (95% CI = 6.0-7.5) to 2.0 (95% CI = 1.4-2.7) ($P < .001$); impairment in sports/recreation decreased from 8.5 (95% CI = 7.9-9.1) to 3.2 (95% CI = 2.6-3.9) ($P < .001$). Frequency of pain medication use decreased from 29 of 40 patients (72.5%) before the procedure to 9 of 40 patients (22.5%) at final follow up ($P < .001$). Localized pain at the injection site was common, but no other adverse events or side effects were reported.

Conclusion: In the setting of tendinosis or arthropathy, dHACM injection was clinically effective in reducing pain and improving function in a majority of adults.

Level of Evidence: IV

Introduction

Degenerative pathology leading to chronic pain of the joints and tendons is highly prevalent and is often difficult to treat successfully, particularly in the long term [1,2]. In particular, tendinopathy and osteoarthritis are both associated with high economic burden and significant disability and loss of function [3,4]. Traditional conservative treatment options have historically been limited to rest, physical therapy, and anti-inflammatory pharmacotherapy including

nonsteroidal anti-inflammatory drugs (NSAIDs) and corticosteroid injections [5,6]. Although these approaches may help to control symptoms, they have limited efficacy and make minimal contributions to the slowing or reversal of degenerative changes [5,7]. As a result, regenerative options, which aim to promote the body's own in vivo healing processes, present a novel and appealing therapeutic avenue [8].

One such emerging regenerative therapy involves the injection of micronized dehydrated human amniotic/chorionic membrane (dHACM) allograft. The use of

human amniotic membrane in a clinical setting dates back more than 100 years [9], with its most well-documented use over the past decade in wound healing for treatment of nonhealing and challenging wounds, such as diabetic foot ulcers. [10] Both in vitro and in vivo studies of the human amniotic membrane have demonstrated that its biological properties reduce inflammation and promote soft tissue healing [9,11]; and enzyme-linked immunosorbent assay analysis of dHACM allograft samples has shown quantifiable levels of anti-inflammatory cytokines, tissue inhibitors of metalloproteinases, and growth factors [12]. A study in a murine model also demonstrated that the dHACM allograft remained bioactive in vivo and was capable of inducing fibroblast proliferation and recruitment of mesenchymal stem cells [12].

Taken together, these features would potentially be useful for accelerating tissue remodeling in chronic, slow-healing musculoskeletal injuries, and counteracting the molecular mediators of degenerative processes such as metalloproteinases [2,7]. Furthermore, amniotic membrane allograft treatment, which involves a single injection of a preformulated powder resuspended in sterile saline solution, may offer several advantages compared to platelet-rich plasma therapy, which requires drawing a patient's blood and introduces variability due to differing preparation methods and variable concentrations of platelets and growth factors [13]. Despite this, the current literature describing the efficacy of amniotic membrane allograft injection in joint and tendon injuries is limited to a small number of podiatric studies reporting improvement in pain symptoms in plantar fasciitis and Achilles tendinosis patients

[14,15], as well as a feasibility study in 6 patients with knee osteoarthritis [16]. Subsequently, the goal of this prospective case series was to evaluate the effectiveness of human amniotic allograft injection in patients with tendinopathy or joint arthropathy/osteoarthritis.

Methods

Study Design, Data Source, and Patients

This study was an expanded review of the medical records of 50 consecutive patients, from the outpatient sports medicine clinic of the principal investigator (A.G.), who received an injection of dHACM from August 2015 through April 2016. A structured interview was administered to patients by telephone to supplement the clinical information available in the chart. If data were present both in chart notes and in the structured interview responses, the data from the chart notes were used to minimize recall bias. The inclusion criteria for the case series were (1) clinical diagnosis of degenerative joint or tendon pathology, and (2) adequate clinical documentation (by chart review or follow-up telephone call) of the patient's pain and functional status before and after dHACM injection. Exclusion criteria were incomplete baseline or follow-up data, and injection of dHACM for both tendon and joint disease within the study period. Institutional Review Board approval was obtained from the Weill Cornell Institutional Review Board. The final analysis was performed on 40 patients, after 10 patients were excluded for incomplete baseline or follow-up data (Figure 1).

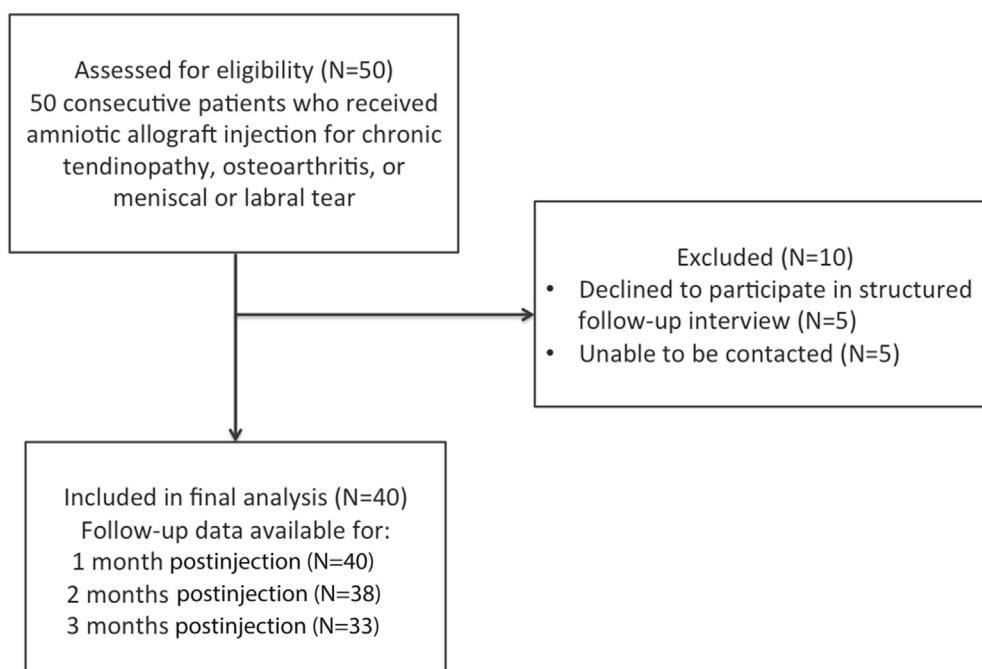


Figure 1. Flow diagram of study patients.

Treatment

All patients received an ultrasound-guided injection of dHACM, performed by the primary investigator. For all injections, 40 mg of dHACM (Amniofix, Mimedx, Marietta, GA) was reconstituted in 1 mL of saline solution as per the manufacturer's directions. A Sonosite XPorte ultrasound machine (Bothell, WA) was used for all injections, with either a 15-6 linear array transducer or a 5-1 curvilinear transducer, depending on the depth of the target. The procedure differed slightly between joint injections and tendon pathologies.

For joint injections, the joint space was visualized with ultrasound [17]. Local anesthesia was obtained with a small amount of lidocaine 1%. Using an in-plane approach, a 22-gauge needle was directed into the joint cavity, with visualization of the needle tip maintained at all times. This technique has a high level of accuracy and minimizes likelihood of injection outside of the joint cavity [18]. All joints, including cervical facet joints, were injected with ultrasound guidance. Once the needle was positioned in the joint, dHACM was injected.

For tendon injections, the tendon was visualized longitudinally with ultrasound, with particular attention to the tendon insertion. The location of tendinopathy was confirmed as a hypoechoic and thickened region, with or without increased Doppler flow. Using ultrasound guidance, a 22-gauge needle was passed directly into the area of tendinopathy, and a limited tenotomy was performed, with approximately 5-10 passes of the needle through the region of tendinosis. After this, the amniotic membrane allograft was injected into the tendon. If more than mild resistance was encountered, the needle was repositioned to the tendon sheath adjacent to the region of tendinopathy, and the remainder of the injectate was injected at this location.

After both joint and tendon injections, patients were instructed to avoid strenuous activity for 3-5 days and to avoid the use of NSAIDs for 2 weeks, given the theoretical interference of these agents with normal wound healing [19]. Postprocedure pain was controlled with ice and acetaminophen 1000 mg up to 3 times per day. No specific physical therapy regimen was prescribed for patients after the injection.

Outcomes and Covariates

Our primary outcome was change in pain scores after the injection of the amniotic membrane allograft. We collected worst pain and average pain scores before the procedure, as well as at 1, 2, and 3 months post-procedure. We also determined an a priori level of pain improvement of 30% as clinically meaningful, and used this as an independent outcome. We chose a 30% improvement based on prior work suggesting that this level is best associated with patients' concept of "much

better" in chronic musculoskeletal pain [20]. Our secondary outcome was change in patient-reported limitation in function based on the Patient-Specific Functional Scale (PSFS), for which we assessed separate scores for activities of daily living (ADLs) and sports and recreation, measured from 0 (no limitation in function) to 10 (completely unable to function because of joint or tendon symptoms) [21,22]. We considered scores of 0-3 to indicate a low degree of functional limitation, 4-7 to indicate a moderate degree of limitation, and 8-10 to indicate a high degree of limitation. Data on functional limitations were reported before the procedure and at final follow-up. We also collected information on age, gender, and use of pain medication before and after the procedure, including acetaminophen, NSAIDs, and opioids.

Statistical Analysis

Paired *t* tests were used to determine the difference in pain levels and functional status between baseline and follow-up time points, and the Shapiro-Francia test of normality was used to assess for normal distribution of variables. To evaluate change in pain medication usage, we used the 2-sample test of proportions. Data were stratified by age, gender, and duration of pain to assess whether our primary and secondary outcomes varied based on these characteristics. Finally, we performed subgroup analysis, evaluating tendon injections and joint injections separately, and used 2-sample *t* tests of equal variances to compare subgroup characteristics and outcomes. At the time of data collection, 38 of 40 patients had data available for only 2 months postinjection, and 33 of 40 patients for 3 months postinjection. Because we assumed that the data at these points were missing at random, we analyzed only the available data rather than imputing the data with replacement values. All data were analyzed using Stata version 14.1 (Stata Corporation, College Station, TX) with α testing for hypothesis testing set at 0.05.

Results

Patient Demographics

A total of 40 patients were included in the final analysis. Of the patients, 20 were treated for joint pathology and 20 were treated for tendon pathology. Joints treated included 8 knee joints, 2 tibiotalar joints, 2 subtalar joints, 3 glenohumeral joints, 3 cervical facet joints, and 2 femoroacetabular joints. Tendons treated included 7 common extensor tendons at the elbow, 3 supraspinatus tendons, 3 conjoint hamstring tendons, 2 gluteus medius tendons, 2 patellar tendons, 1 Achilles tendon, 1 fibularis longus tendon, and 1 iliopsoas tendon. Baseline characteristics of the patients are shown in Table 1. There were slightly more female

Table 1
Subject baseline characteristics

	Total Cohort, Mean (SD) or %, N = 40	Joint Pathology, Mean (SD) or %, n = 20	Tendon Pathology, Mean (SD) or %, n = 20
Demographics			
Age, years	50.7 (12.4)	51.3 (12.0)	50.2 (13.1)
Gender, % female	52.5	60.0	45.0
Pain and functional history			
Months of pain before procedure, median (range)	9 (1-108)	9 (3-108)	10.5 (1-96)
Worst pain, NRS, 0-10 scale	8.3 (1.3)	8.4 (1.4)	8.3 (1.4)
Average pain, NRS, 0-10 scale	6.4 (2.0)	6.6 (2.3)	6.2 (1.6)
ADL limitation, PSFS, 0-10 scale	6.8 (1.9)	7.1 (2.0)	6.4 (1.9)
Sports/recreation limitation, 0-10 scale	8.5 (1.8)	8.4 (2.0)	8.6 (1.7)
Treatment history			
Pain medication use, any, %	72.5	80	65
NSAID	55	70	40
Acetaminophen	17.5	10	25
Opioid	5	5	5
Alternative treatments tried, any, %	77.5	75	80
Physical therapy	52.5	40	65
Injections	40	50	30
Surgery (arthroscopy)	5	10	0
Other (acupuncture, dry needling, joint aspiration, brace)	17.5	15	20

SD = standard deviation; NRS = numeric rating scale; ADL = activity of daily living; PSFS = Patient-Specific Functional Scale; NSAID = nonsteroidal anti-inflammatory drug.

patients in the joint pathology subgroup and slightly more male patients in the tendon subgroup. Patients were otherwise comparable between groups.

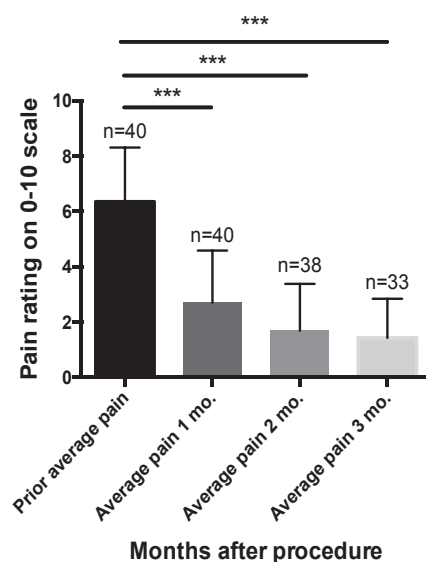
Change in Pain Scores

The changes in pain scores are shown in Figure 2. For the cohort as a whole, average patient reported pain scores decreased from a baseline value of 6.4 (95% confidence interval [CI] = 5.77-7.0) to 2.7 (95% CI =

2.1-3.3) ($P < .001$) at 1 month, 1.7 (95% CI = 1.1-2.2; $P < .001$) at 2 months, and 1.4 (95% CI = 0.9-1.9; $P < .001$) at 3 months. Similar trends were seen for patient-reported worst pain, which decreased from a baseline value of 8.3 (95% CI = 7.9-8.8) to 4.4 (95% CI = 3.9-5.0) ($P < .001$) at 1 month, 3.3 (95% CI = 2.7-3.9; $P < .001$) at 2 months, and 2.6 (95% CI = 2.0-3.3; $P < .001$) at 3 months.

In addition to average pain scores, we evaluated the percentage of patients reaching a clinically meaningful improvement in pain, defined as 30% decrease in

A Patient-reported average pain: Mean±SD



B Patient-reported worst pain scores: Mean±SD

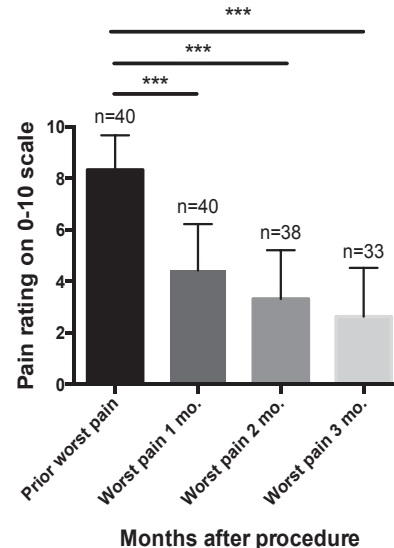


Figure 2. (A) Changes in patient-reported average pain scores from baseline to 3-month follow-up. (B) Changes in patient-reported worst pain from baseline to 3 month follow up. *** $P < .001$.

average and worst pain levels. At 1 month, 75% of patients had experienced a clinically meaningful improvement in worst pain, which increased to 84% at 2 months and to 91% at 3 months. Similarly, 68% of patients had experienced a clinically meaningful improvement in average pain at 1 month, which increased to 82% at 2 months and to 91% at 3 months (Figure 3).

Change in Function

As a whole, patients reported moderate to high levels of functional impairment before the procedure, with an average score of 6.8 (95% CI = 6.0-7.5) on the ADL subscale of the PSFS, and 8.5 (95% CI = 7.9-9.1) on the sports and recreation subscale of the PSFS. At final follow-up, the mean ADL limitation had decreased to a low level at 2.0 (95% CI = 1.4-2.7), and sports and recreation limitation had similarly decreased to a low level at 3.2 (95% CI = 2.6-3.9).

Change in Medication Use

Change in medication use is shown in Figure 4. There was a marked decrease in overall medication use after the procedure. Overall, 31 of 40 patients were using some medication for pain before the procedure; this decreased to 9 patients after the procedure ($P < .001$). The decrease in NSAID use was significant ($P < .001$), whereas the decrease in acetaminophen ($P = .15$) and opioid ($P = .31$) use was not statistically significant.

Adverse Events

No serious adverse events occurred in any patient. Localized pain after the injection was present in 72.5%, with a mean of 2.25 days (standard deviation, 2.2 days) of pain after the procedure. Postprocedure pain was managed with oral acetaminophen and application of ice.

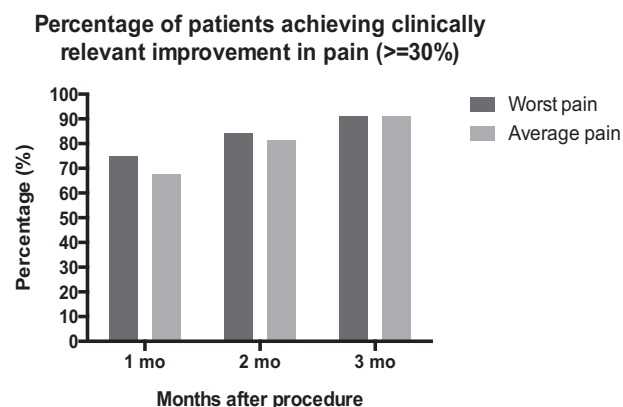


Figure 3. Clinical success rates (>30% pain improvement on numeric rating scale) after dehydrated human amnion/chorion membrane (dHACM) injection.

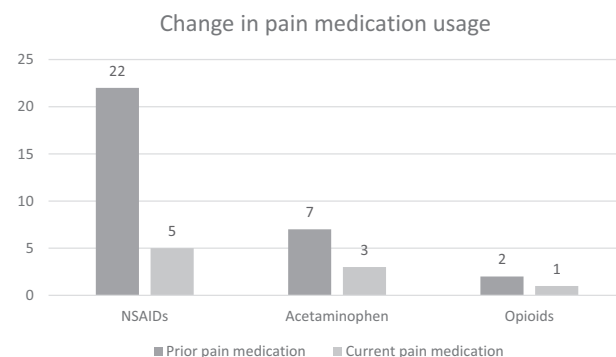


Figure 4. Change in pain medication use after dehydrated human amnion/chorion membrane (dHACM) injection. Pain medication use decrease from baseline to final follow-up.

Patient Satisfaction

Overall levels of satisfaction were high with the procedure. In all, 92.5% of patients were satisfied; 87.5% reported that they would recommend the procedure for other patients with similar joint or tendon issues; and 85% reported that they would repeat the procedure for a similar problem in the future.

Subgroup Analysis: Joint Versus Tendon Pathology

Because of the different pathogenesis and natural history of joint and tendon disorders, we performed subgroup analysis of the cohort, dividing the patients by pathologic category into joint disease ($n = 20$) or tendon disease ($n = 20$). Differences between these groups are shown in Table 2. When evaluating changes in pain scores in these 2 groups, there were no significant differences between patients with tendon pathology and joint pathology. There was a trend toward patients with joint pathology showing a more rapid decrease in average and worst pain levels, with larger reported decreases in average and worst pain at 1 month versus those in the group with tendon pathology. However, these differences did not reach levels of significance. There was a significant difference between the 2 groups in the percentage of patients taking NSAIDs for pain relief. In the joint group, the prevalence of NSAID use was 70% before the procedure and 10% after the procedure. This compared with a prevalence of 40% before the procedure and 15% after the procedure for the tendon group. Postprocedure pain was similar for both groups, as was overall level of satisfaction with the procedure.

Discussion

To our knowledge, this is the first report of a cohort of patients with joint and tendon pathology treated with dHACM injection. The procedure was well

Table 2
Subgroup characteristics for dHACM cohort

Characteristic	Joint Pathology, n = 20	Tendon Pathology, n = 20	P Value
Worst pain, 0-10 scale			
Baseline	8.40 (1.4)	8.25 (1.4)	.73
1 mo	4.20 (1.8)	4.65 (1.8)	.44
2 mo	3.37 (2.0)	3.26 (1.8)	.87
3 mo	2.69 (2.1)	2.59 (1.7)	.88
Average pain, 0-10 scale			
Baseline	6.55 (2.3)	6.15 (1.6)	.52
1 mo	2.35 (1.7)	3.05 (2.0)	.24
2 mo	1.58 (1.6)	1.79 (1.8)	.71
3 mo	1.38 (1.5)	1.47 (1.4)	.85
ADL function, 0-10 scale			
Preprocedure	5.00 (3.7)	4.45 (3.4)	.63
Postprocedure	1.55 (2.0)	1.30 (1.4)	.65
Sport/recreation function, 0-10 scale			
Preprocedure	8.35 (2.0)	8.20 (2.5)	.84
Postprocedure	3.50 (2.2)	2.80 (1.7)	.27
Pain medication use before injection, n (%)	16 (80%)	13 (65%)	.29
NSAID	14 (70%)	8 (40%)	.057
Acetaminophen	2 (10%)	5 (25%)	.21
Opioid	1 (5%)	1 (5%)	1.0
Current pain medication use	5 (25%)	4 (20%)	.71
NSAID	2 (10%)	3 (15%)	.63
Acetaminophen	2 (10%)	1 (5%)	.55
Opioid	1 (5%)	0 (0%)	.31
Patients experiencing pain at injection site	13 (65%)	16 (80%)	.29
Days of pain at injection site after procedure	2.05 (2.4)	2.45 (2.1)	.58
Satisfied	18 (90%)	19 (95%)	.55
Would recommend	18 (90%)	17 (85%)	.63
Would repeat	18 (90%)	16 (80%)	.38

dHACM = dehydrated human amnion/chorion membrane; ADL = activity of daily living; NSAID = nonsteroidal anti-inflammatory drug.

tolerated, with no serious adverse events, and only localized tissue pain for an average of 2 days after the procedure. Our main findings are marked and continued improvement in pain and function at 1-, 2-, and 3-month follow-up. Findings were similar between patients with joint pathology and tendon pathology, and patients reported high levels of satisfaction with the procedure. Taken together, our findings suggest that dHACM may serve as a promising and largely unexplored regenerative treatment option with the potential to improve self-reported pain and function over 3 months of follow-up.

These results are of particular interest, given the challenges of treating patients with chronic musculoskeletal pain. In our cohort, patients had symptoms for an average of 22.3 months before the procedure, and more than three-fourths had tried some form of prior treatment without success. These patterns of symptom chronicity and poor outcomes with standard conservative measures are familiar to clinicians who treat patients with osteoarthritis and tendinopathy.

Because of the novelty of dHACM injection, there are few studies that are directly comparable to ours. It may be instructive to compare our outcomes with more established regenerative treatment options, including platelet-rich plasma (PRP) injection. A recent systematic review [23] evaluating PRP in the treatment of tendinopathy and osteoarthritis included 54 randomized trials and 8 cohort studies. PRP was found to be superior to active control in intermediate- and long-term treatment of tendinopathy involving the elbow, knee, and shoulder, and was superior to hyaluronic acid in the treatment of knee osteoarthritis when measuring function and pain. Furthermore, although short-term responses to pain were similar when comparing PRP to conventional injection therapies, PRP tended to show more benefits at intermediate and long term when compared with these treatments, consistent with the theoretical premise of a regenerative approach. The results of our study are broadly consistent with these findings: patients in our cohort tended to show improvements in pain and function that increased over time, rather than returning toward baseline levels.

The magnitude of clinical improvement that our cohort demonstrated with dHACM should be considered in relation to other reported regenerative treatments. In a large randomized controlled trial evaluating PRP as a treatment for lateral epicondylitis [24], when clinical success was defined similarly to that in our cohort (>25% improvement in VAS), 75% of patients reached clinical success at 12 weeks. This compares to a clinical success rate of 94% reported in our cohort of patients with tendinosis. Similarly, our results can be considered in comparison with 2 studies evaluating PRP in the treatment of osteoarthritis. In those studies, clinical success was considered present when patients reported a decrease of 30% on the Western Ontario and McMaster Universities Osteoarthritis Index (WOMAC) pain subscale [25,26]. In these 2 studies, clinical success rates were observed in 57% of patients with hip osteoarthritis at 6 months [25] and in 83% of patients with knee osteoarthritis at 6 months [26]. This compares with a clinical success rate of 88% in our cohort of patients with arthropathy.

Overall, biologic treatments such as PRP appear to provide superior long-term pain relief compared to more traditional methods such as dry needling or extracorporeal shock wave therapy (ECSW), in which no biologically active substances are injected into the area of injury and the goal is generally believed to be the promotion of a novel healing response through mechanical stimulation of the injured area. For instance, a direct comparison between ECSW and PRP for treatment of patellar tendinosis showed initial clinical benefit for both groups but markedly superior outcomes at 6 and 12 months in the PRP group [27]. In that cohort of patients, pain measured by a 0-10 visual analogue scale decreased in the PRP group from 6.6 to

3.2 at 2 months, 2.4 at 6 months, and 1.5 at 12 months. In contrast, the ECSW group showed a decrease in pain from 6.3 at baseline to 3.9 at 2 months, 3.9 at 6 months, and 3.2 at 12 months. The magnitude of pain improvement in our cohort is similar to the results in the PRP group in this study.

Although dHACM treatment is postulated to promote soft tissue healing, the mechanisms by which it may accomplish this remain unclear. Relevant to the present study, the divergent pathogenesis of tendinopathy and osteoarthritis suggest that the mechanism of action may indeed be different in these 2 treatment groups. dHACM as used in the current study contains quantifiable levels of more than 200 biologic factors as established by enzyme-linked immunosorbent assay. Of these, a reasonable functional grouping would include growth factors, interleukins, and tissue inhibitors of metalloproteinases [12]. The complexity and interaction of such a large number of injected biologic factors precludes a clear hypothesis as to the mechanisms of action, but in vitro analysis demonstrates that dHACM affects mesenchymal stem cells, fibroblasts, and leukocytes [8,12,15]. Therefore, immunomodulation, progenitor cell recruitment, cell proliferation, and metalloproteinase modulation are likely important effects of dHACM injection in both tendinopathy and arthritis, although the cascades of effect remain to be delineated in each of these pathologies.

A few important differences between dHACM and PRP can be considered. First, in comparison to PRP, in which all active biologic factors are released into the joint or tendon simultaneously upon platelet activation, dHACM contains active factors that elute from the tissue more slowly over a period of days to weeks [12]. From a theoretical standpoint, the continued presence of active factors over a prolonged period of time may enhance an in vivo response to the injected materials. Second, both the absolute concentration as well as the relative ratio of the growth factors, cytokines, and tissue inhibitors of metalloproteinases differs between PRP and dHACM. Variation in PRP may be due to the preparation method as well as to patient factors such as age and concomitant NSAID use [28,29]. Because the effect of both of these treatments relies on a dynamic and complex interplay of cell signaling and anabolic and catabolic cascades, the differences between the active biologic components in PRP and dHACM present a rich opportunity for further study.

There are some important limitations to our current study. First, our patient population was heterogeneous, including patients with both tendon and joint pathology. Although subgroup analysis demonstrated similar patterns of improvement in patients with tendinopathy and those with arthropathy, we realize that it is difficult to generalize these results to more homogeneous groups of patients or specific diagnostic categories. An additional limitation is the lack of a control group or comparator

treatment, and thus no strong conclusions can be drawn regarding the cause of patient improvement. To address this limitation, future studies will prospectively compare dHACM injection with an active control treatment, such as a corticosteroid injection. However, the mean duration of pain in our study was 22 months; spontaneous improvement over 1-3 months is clinically unlikely in this patient population, suggesting that the effects that we observed were related largely to dHACM injection.

Conclusion

Injection of dHACM was well tolerated in a cohort of 40 adult patients with chronic tendinopathy and arthropathy, although a localized increase in pain can be expected temporarily after the injection. In addition, dHACM injection was found to reduce pain and to improve function at 1-, 2-, and 3-month follow-up, with a significant decrease in pain medication use and with high patient satisfaction with the procedure. Future studies will seek to prospectively compare the effectiveness of dHACM versus an active control injection as well as against PRP and other regenerative therapies.

References

1. Litwic A, Edwards MH, Dennison EM, Cooper C. Epidemiology and burden of osteoarthritis. *Br Med Bull* 2013;105:185-199.
2. Rees JD, Wilson AM, Wolman RL. Current concepts in the management of tendon disorders. *Rheumatology (Oxford)* 2006;45:508-521.
3. Hopkins C, Fu S-C, Chua E, et al. Critical review on the socio-economic impact of tendinopathy. *Asia-Pacific J Sports Med Arthrosc Rehabil Technol* 2016;4:9-20.
4. Bitton R. The economic burden of osteoarthritis. *Am J Manag Care* 2009;15:S230-S235.
5. Skjong CC, Meiningner AK, Ho SSW. Tendinopathy treatment: Where is the evidence? *Clin Sports Med* 2012;31:329-350.
6. Sinusas K. Osteoarthritis: Diagnosis and treatment. *Am Fam Physician* 2012;85:49-56.
7. Zhang W, Ouyang H, Dass CR, Xu J. Current research on pharmacologic and regenerative therapies for osteoarthritis. *Bone Res* 2016;4:15040.
8. Riboh JC, Saltzman BM, Yanke AB, Cole BJ. Human amniotic membrane-derived products in sports medicine: Basic science, early results, and potential clinical applications. *Am J Sports Med* 2015;1-11.
9. Parolini O, Alviano F, Bagnara GP, et al. Concise review: Isolation and characterization of cells from human term placenta: Outcome of the First International Workshop on Placenta Derived Stem Cells. *Stem Cells* 2008;26:300-311.
10. Lintzeris D, Yarrow K, Johnson L, et al. Use of a dehydrated amniotic membrane allograft on lower extremity ulcers in patients with challenging wounds: A retrospective case series. *Ostomy/Wound Manag* 2015;61:30-66.
11. Niknejad H, Peirovi H, Jorjani M, Ahmadiani A, Ghanavi J, Seifalian AM. Properties of the amniotic membrane for potential use in tissue engineering. *Eur Cells Mater* 2008;15:88-99.
12. Koob TJ, Rennert R, Zabek N, et al. Biological properties of dehydrated human amnion/chorion composite graft: Implications for chronic wound healing. *Int Wound J* 2013;10:493-500.

13. Mazzocca AD, McCarthy MBR, Chowanec DM, et al. Platelet-rich plasma differs according to preparation method and human variability. *J Bone Joint Surg Am* Vol 2012;94:308-316.
14. Werber B. Amniotic tissues for the treatment of chronic plantar fasciosis and Achilles tendinosis. *J Sports Med* 2015;2015:1-6.
15. Zelen CM, Poka A, Andrews J. Prospective, randomized, blinded, comparative study of injectable micronized dehydrated amniotic/chorionic membrane allograft for plantar fasciitis—a feasibility study. *Foot Ankle Int* 2013;34:1332-1339.
16. Vines J, Aliprantis A, Gomoll A, Farr J. Cryopreserved amniotic suspension for the treatment of knee osteoarthritis. *J Knee Surg* 2016;29:443-450.
17. Malanga G, Mautner K. Atlas of Ultrasound-Guided Musculoskeletal Injections. New York: McGraw-Hill Professional; 2014.
18. Finnoff JT, Hall MM, Adams E, et al. American Medical Society for Sports Medicine (AMSSM) position statement: Interventional musculoskeletal ultrasound in sports medicine. *PM R* 2015;7:151-168.
19. Rand E, Gellhorn AC. The healing cascade: Facilitating and optimizing the system. *Phys Med Rehabil Clin North Am* 2016;27:765-781.
20. Salaffi F, Stancati A, Silvestri CA, Ciapetti A, Grassi W. Minimal clinically important changes in chronic musculoskeletal pain intensity measured on a numerical rating scale. *Eur J Pain* 2012;8:283-291.
21. Westaway MD, Stratford PW, Binkley JM. The patient-specific functional scale: Validation of its use in persons with neck dysfunction. *J Orthop Sports Phys Ther* 1998;27:331-338.
22. Berghmans DDP, Lenssen AF, van Rhijn LW, de Bie RA. The patient-Specific Functional Scale: Its reliability and responsiveness in patients undergoing a total knee arthroplasty. *J Orthop Sports Phys Ther* 2015;45:550-556.
23. Hashimoto R, Brodt E, Skelly A. Autologous Blood or Platelet-Rich Plasma Injections. Washington State Health Care Authority Health Technology Assessment. 2016. Available at <http://www.hca.wa.gov/about-hca/health-technology-assessment/autologous-blood-or-platelet-rich-plasma-injections>.
24. Mishra AK, Skrepnik NV, Edwards SG, et al. Efficacy of platelet-rich plasma for chronic tennis elbow: A double-blind, prospective, multicenter, randomized controlled trial of 230 patients. *Am J Sports Med* 2013;42:463-471.
25. Sánchez M, Guadilla J, Fiz N, Andia I. Ultrasound-guided platelet-rich plasma injections for the treatment of osteoarthritis of the hip. *Rheumatology (Oxford)* 2012;51:144-150.
26. Vaquerizo V, Plasencia MÁ, Arribas I, et al. Comparison of intra-articular injections of plasma rich in growth factors (PRGF-Endoret) versus Durolane hyaluronic acid in the treatment of patients with symptomatic osteoarthritis: A randomized controlled trial. *Arthroscopy* 2013;29:1635-1643.
27. Vetrano M, Castorina A, Vulpiani MC, Baldini R, Pavan A, Ferretti A. Platelet-rich plasma versus focused shock waves in the treatment of jumper's knee in athletes. *Am J Sports Med* 2013;41:795-803.
28. Mazzocca AD, McCarthy MBR, Chowanec DM, et al. Platelet-rich plasma differs according to preparation method and human variability. *J Bone Joint Surg* 2012;94:308-316.
29. Hire JM, Evanson JL, Johnson PC, et al. Variance of matrix metalloproteinase (MMP) and tissue inhibitor of metalloproteinase (TIMP) concentrations in activated, concentrated platelets from healthy male donors. *J Orthop Surg Res* 2014;9:29.

Disclosure

A.C.G. Division of Rehabilitation Medicine, Weill Cornell Medical College, 525 E. 68 Street, B16, New York, NY 10065. Address correspondence to: A.C.G.; e-mail: Alg9109@med.cornell.edu

Disclosures related to this publication: educational lecture honoraria, MiMedx

A.H. Warren Alpert Medical School at Brown University, Providence RI
Disclosures: nothing to disclose

Submitted for publication December 21, 2016; accepted April 15, 2017.